

# Bevacizumab Reverses Need for Liver Transplantation in Hereditary Hemorrhagic Telangiectasia

Andrew Mitchell,<sup>1\*</sup> Leon A. Adams,<sup>1,3\*</sup> Gerry MacQuillan,<sup>1,3</sup> Jon Tibballs,<sup>2</sup> Rohan vanden Driesen,<sup>2</sup> and Luc Delriviere<sup>1</sup>

<sup>1</sup>Western Australian Liver Transplant Service and <sup>2</sup>Department of Radiology, Sir Charles Gairdner Hospital, Nedlands, Australia; and <sup>3</sup>School of Medicine and Pharmacology, University of Western Australia, Nedlands, Australia

Hereditary hemorrhagic telangiectasia (HHT) is an autosomal dominant disease characterized by mucocutaneous and visceral telangiectasia. Hepatic involvement with vascular malformations may lead to portal hypertension, biliary ischemia, and high-output cardiac failure. Liver transplantation is indicated for life-threatening disease but carries significant risk from surgery and chronic immunosuppression. We report a case of a 47-year-old woman with HHT successfully treated with the vascular endothelial growth factor (VEGF) antibody bevacizumab. The patient was referred for consideration of liver transplantation because of hepatic HHT leading to high-output cardiac failure, diuretic resistant ascites, cholestasis, and malnutrition. As she was considered a high-risk candidate for transplantation, she underwent 6 courses of bevacizumab (5 mg/kg) over 12 weeks. A dramatic improvement in her clinical state was observed after 3 months with reversal of cholestasis, resolution of cardiac failure and ascites, and improvement in nutritional status with a 10% dry weight increase. Treatment induced a marked reduction in liver vascularity and halving of her liver volume from 4807 to 2269 mL over 6 months. This was associated with normalization of her cardiac output from 10.2 to 5.1 L/minute. Correspondingly, she ceased diuretic medications, returned to full-time work, and was delisted as a transplant candidate. She remains well 6 months after completing treatment. In conclusion, antagonism of VEGF receptors led to a dramatic regression of hepatic vascular malformations and reversal of high-output cardiac failure and complications of portal hypertension in this patient with HHT. Bevacizumab may potentially alleviate the need for liver transplantation in this group of patients. *Liver Transpl* 14:210-213, 2008. © 2008 AASLD.

Received September 12, 2007; accepted December 4, 2007.

Hereditary hemorrhagic telangiectasia (HHT), or Rendu-Osler-Weber syndrome, is inherited in an autosomal dominant fashion and affects approximately 1 of 5000 individuals.<sup>1</sup> The syndrome is characterized by abnormal mucocutaneous and visceral telangiectasia. The liver is commonly affected by vascular malformations (41%-78%) that may produce portovenous (portal vein to hepatic vein), arteriovenous (hepatic artery to hepatic vein), and arterioportal (hepatic artery to portal vein) shunting.<sup>1</sup> Although hepatic involvement is often asymptomatic, the commonest clinical manifestation is high-output cardiac failure secondary to intrahepatic

shunting leading to breathlessness and fluid retention. Arterioportal shunting may result in portal hypertension with ascites and variceal bleeding, whereas arteriovenous shunting can cause biliary ischemia with subsequent necrosis and sclerosing cholangitis.<sup>1,2</sup> Perfusional changes within the liver may also lead to nodular regenerative hyperplasia and focal nodular hyperplasia. Mucocutaneous involvement commonly causes epistaxis and gastrointestinal bleeding with resultant iron-deficiency anemia. Pulmonary arteriovenous malformations occur in up to one-third of patients, potentially leading to intrapulmonary shunting, hypoxia, and

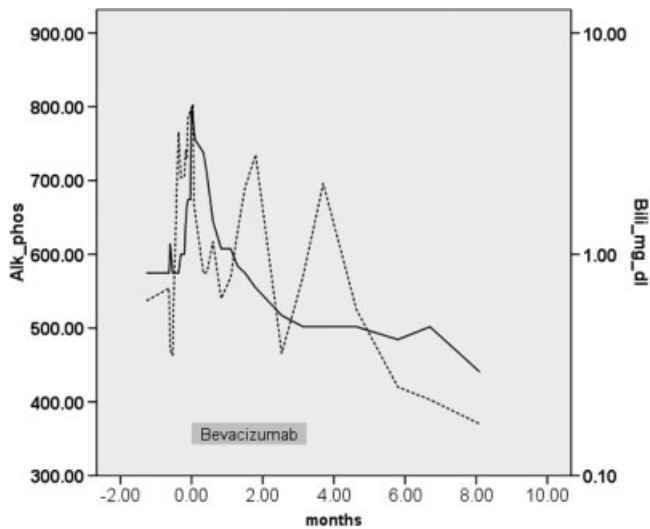
**Abbreviations:** A, ascites; HA, hepatic artery; HHT, hereditary hemorrhagic telangiectasia; LVED, left ventricular end-diastolic; LVES, left ventricular end-systolic; MR, magnetic resonance; PV, portal vein; VEGF, vascular endothelial growth factor.

\*These authors contributed equally to this study.

Address reprint requests to Leon A. Adams, School of Medicine and Pharmacology, University of Western Australia, Sir Charles Gairdner Hospital, Verdun Street, Nedlands, W.A. 6009, Australia. Telephone: 618-9346-3228; FAX: 618-9346-3098; E-mail: leon.adams@uwa.edu.au

DOI 10.1002/lt.21417

Published online in Wiley InterScience (www.interscience.wiley.com).



**Figure 1. Dramatic improvement of cholestatic liver enzymes with bevacizumab. Bilirubin is represented by a continuous line; alkaline phosphatase is represented by a broken line.**

hemoptysis,<sup>3</sup> whereas cerebral and spinal malformations may present with seizures, hemorrhage, headaches, and neurological deficits.<sup>4</sup>

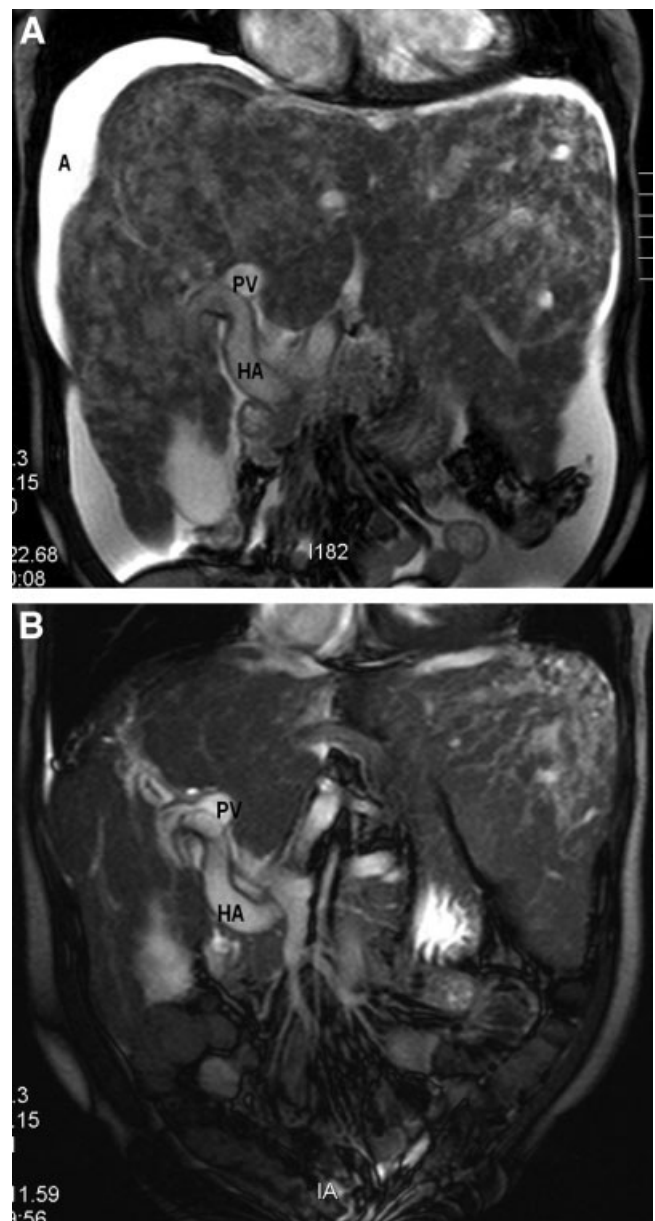
Currently, treatment of patients with hepatic HHT is primarily symptomatic without alteration of the underlying pathological neovascularization. Hepatic arterial embolization or occlusion is associated with significant morbidity and mortality and is not recommended outside palliative circumstances.<sup>1-5</sup> Liver transplantation is curative but involves an 18% risk of acute mortality as well as problems of long-term immunosuppression.<sup>5</sup> We present a case of a patient with severe HHT who responded dramatically to treatment with bevacizumab, a vascular endothelial growth factor (VEGF) antibody, which obviated the need for liver transplantation.

## CASE REPORT

A 47-year-old woman was referred for assessment for liver transplantation due to HHT complicated by high-output cardiac failure, portal hypertension, cholestasis, and malnutrition. She had been diagnosed with HHT as a teenager and fulfilled consensus diagnostic criteria requiring the presence of epistaxis, telangiectasia on her lips and oral cavity, visceral involvement of her liver, and a family history.<sup>6</sup> Her mother had died at the age of 56 of liver failure secondary to HHT, her brother and sister suffered epistaxis, and a cousin had received a liver transplant for HHT. After her diagnosis, she had received periodic iron infusions for anemia but had otherwise been well and was working full-time.

Over a 6-month period, she developed worsening high-output cardiac failure, ascites, and bilateral pleural effusions that became diuretic-resistant and required large-volume paracentesis. She had progressive lethargy and a reduction in her performance status such that she was unable to walk more than 30 m or

stand for a prolonged length of time. This was associated with a progressive loss of weight and muscle mass, with her dry weight body mass index falling from 21.7 to 17.9 kg/m<sup>2</sup>. Serum biochemistry demonstrated progressive cholestasis (Fig. 1). Liver magnetic resonance (MR) angiography confirmed an enormous liver (4807 mL) and massive arteriovenous malformations (Fig. 2A). Cardiac MR demonstrated severely dilated atria and ventricles and a high resting cardiac output (Table 1) despite beta-blockade. Pulmonary and intracranial vascular malformations were not present on computed tomography or MR scans. Endoscopy demonstrated



**Figure 2. Magnetic resonance scans with intravenous gadolinium before and 6 months after bevacizumab, demonstrating a marked reduction in hepatic size and vascularity and resolution of ascites. Abbreviations: A, ascites; HA, hepatic artery; PV, portal vein.**

TABLE 1. Reduction in Liver Volume and Cardiac Output with Bevacizumab

Time	Courses of Bevacizumab (5 mg/kg)	Liver Volume (mL)	LVED Volume (mL)	LVES Volume (mL)	Cardiac Output (L/minute)
0 months	0 courses	4807	192	72	10.2
3 months	6 courses	3151	174	64	6.3
6 months	—	2269	182	58	5.1

Abbreviations: LVED, left ventricular end-diastolic; LVES; left ventricular end-systolic.

grade II esophageal varices. Because of her poor cardiac status and malnutrition, a bridge therapy was felt necessary. After informed consent was obtained from the patient, 6 courses of bevacizumab (5 mg/kg) were given over a 3-month period.

An immediate improvement in her cholestatic liver enzymes was observed (Fig. 1), followed by a dramatic improvement in her clinical state. Over the course of 3 months, her cardiac failure, ascites, and pleural effusions resolved clinically and radiologically (Fig. 2B). This was associated with improvement in her nutritional status and a 10% increase in dry weight. By 6 months, all symptoms had resolved, and she was able to cease all medications and return to full-time work. She was subsequently delisted as a transplant candidate. Serial MR liver and cardiac scans (Table 1) confirmed a marked diminution of hepatic vascularity, a 2-fold reduction in liver volume, and normalization of cardiac output. Her previous grade II esophageal varices were markedly small and barely visible on follow-up endoscopy. She remains well 6 months after completing treatment.

## DISCUSSION

VEGF is a key regulator of angiogenesis and is up-regulated in a variety of disease states including malignancy, ocular disease, and inflammatory conditions.<sup>7</sup> Vessels formed by VEGF are disorganized and tortuous, similar to those observed in patients with HHT.<sup>7</sup> Not surprisingly, serum and tissue expression of VEGF is increased in patients with HHT and correlates with microvessel density.<sup>8</sup> The genetic mutations of HHT affect endoglin (HHT type 1), activin receptor-like kinase 1 (HHT type 2), and the SMAD 4 gene. These genes are involved in the transforming growth factor- $\beta$  signaling pathway, which is a potent stimulator of VEGF production.<sup>9</sup> Thus, blocking VEGF represents a logical therapeutic target for HHT.

Bevacizumab is a humanized recombinant monoclonal antibody against VEGF. It induces the arrest of endothelial cell proliferation, thereby preventing vessel growth and causing the regression of existing vessels by increasing endothelial cell death.<sup>10</sup> Bevacizumab is effective in diseases of abnormal angiogenesis such as non-small-cell lung cancer and metastatic colorectal cancer, where it improves survival.<sup>11,12</sup> Furthermore, it improves visual acuity in age-related macular degener-

ation by reducing choroidal neovascularization.<sup>13</sup> When given in combination with pemetrexed for treatment of malignant mesothelioma, bevacizumab was noted to reduce the severity of epistaxis and transfusion requirements in 1 patient who had concomitant HHT.<sup>14</sup> The case that we describe here is the first in which bevacizumab has been used to deliberately ameliorate life-threatening complications of HHT. Complete resolution of all symptomatic manifestations was observed and objectively quantified. Therapy with bevacizumab was well tolerated with minimal toxicity. In contrast, the current treatment options for advanced symptomatic hepatic HHT of hepatic arterial ligation or liver transplantation carry significant risk of morbidity and mortality.

In conclusion, bevacizumab induced a strong biological and clinical response in this patient with symptomatic hepatic HHT. Biological agents targeting angiogenic growth factors represent a novel form of treatment for patients with HHT with the potential to alleviate disease-related morbidity and mortality. The impressive response of this case mandates the further use of such agents in a clinical trial setting.

## REFERENCES

- Garcia-Tsao G. Liver involvement in hereditary hemorrhagic telangiectasia (HHT). *J Hepatol* 2007;46:499-507.
- Garcia-Tsao G, Korzenik JR, Young L, Henderson KJ, Jain D, Byrd B, et al. Liver disease in patients with hereditary hemorrhagic telangiectasia. *N Engl J Med* 2000;343:931-936.
- Cottin V, Dupuis-Girod S, Lesca G, Cordier JF. Pulmonary vascular manifestations of hereditary hemorrhagic telangiectasia (Rendu-Osler disease). *Respiration* 2007;74:361-378.
- Matsubara S, Mandzia JL, ter Brugge K, Willinsky RA, Faughnan ME. Angiographic and clinical characteristics of patients with cerebral arteriovenous malformations associated with hereditary hemorrhagic telangiectasia. *AJNR Am J Neuroradiol* 2000;21:1016-1020.
- Lerut J, Orlando G, Adam R, Sabba C, Pfizmann R, Klompauer J, et al. Liver transplantation for hereditary hemorrhagic telangiectasia: report of the European liver transplant registry. *Ann Surg* 2006;244:854-862; discussion 62-64.
- Shovlin CL, Guttmacher AE, Buscarini E, Faughnan ME, Hyland RH, Westermann CJ, et al. Diagnostic criteria for hereditary hemorrhagic telangiectasia (Rendu-Osler-Weber syndrome). *Am J Med Genet* 2000;91:66-67.

7. Carmeliet P, Jain RK. Angiogenesis in cancer and other diseases. *Nature* 2000;407:249-257.
8. Sadick H, Naim R, Gossler U, Hormann K, Riedel F. Angiogenesis in hereditary hemorrhagic telangiectasia: VEGF165 plasma concentration in correlation to the VEGF expression and microvessel density. *Int J Mol Med* 2005;15:15-19.
9. Sadick H, Riedel F, Naim R, Goessler U, Hormann K, Hafner M, et al. Patients with hereditary hemorrhagic telangiectasia have increased plasma levels of vascular endothelial growth factor and transforming growth factor-beta1 as well as high ALK1 tissue expression. *Haematologica* 2005;90:818-828.
10. Carmeliet P. Angiogenesis in life, disease and medicine. *Nature* 2005;438:932-936.
11. Sandler A, Gray R, Perry MC, Brahmer J, Schiller JH, Dowlati A, et al. Paclitaxel-carboplatin alone or with bevacizumab for non-small-cell lung cancer. *N Engl J Med* 2006;355:2542-2550.
12. Hurwitz H, Fehrenbacher L, Novotny W, Cartwright T, Hainsworth J, Heim W, et al. Bevacizumab plus irinotecan, fluorouracil, and leucovorin for metastatic colorectal cancer. *N Engl J Med* 2004;350:2335-2342.
13. Michels S, Rosenfeld PJ, Puliafito CA, Marcus EN, Venkatraman AS. Systemic bevacizumab (Avastin) therapy for neovascular age-related macular degeneration: twelve-week results of an uncontrolled open-label clinical study. *Ophthalmology* 2005;112:1035-1047.
14. Flieger D, Hainke S, Fischbach W. Dramatic improvement in hereditary hemorrhagic telangiectasia after treatment with the vascular endothelial growth factor (VEGF) antagonist bevacizumab. *Ann Hematol* 2006;85:631-632.